

Original article

Phenotypic analysis of pyrin-associated autoinflammation with neutrophilic dermatosis patients during treatment

Erika Van Nieuwenhove^{1,2,3,4,*}, Ellen De Langhe^{5,6,*}, James Dooley⁷, Joost Van Den Oord⁸, Mohammad Shahrooei^{1,9}, Nima Parvaneh^{10,11}, Vahid Ziaee^{12,13}, Sinisa Savic^{14,15}, Mark Kacar^{14,15}, Xavier Bossuyt¹⁶, Stephanie Humblet-Baron^{1,2}, Adrian Liston^{1,2,6,*} and Carine Wouters^{1,3,4,*}

Abstract

Objective. In 2016 specific heterozygous gain-of-function mutations in the Mediterranean fever gene *MEFV* were reported as causal for a distinct autoinflammatory disease coined pyrin-associated autoinflammation with neutrophilic dermatosis (PAAND). We sought to provide an extended report on clinical manifestations in PAAND patients to date and evaluate the efficacy and safety of treatment with the IL-1-blocking agent anakinra.

Methods. We undertook an open-label pilot study with anakinra. Three patients were recruited in a preliminary phase of the study with the intention to expand the treatment cohort in case of a favourable response. Acute-phase reactants and plasma cytokine levels were monitored throughout. Skin biopsies at baseline and at week 12 were stained for relevant cytokines. Available clinical data on treatment responses were retrospectively collected on additional patients.

Results. The three patients from the preliminary phase of the study [patients 1–3 (P1–P3)] demonstrated one failed and two partial treatment responses, where one patient opted to continue treatment with anakinra and the other favoured adalimumab. While a partial systemic response was observed, there was no appreciable effect of anakinra on the prominent cutaneous manifestations, reflected in residual local inflammatory cytokine expression in lesional skin. These observations did not warrant further expansion of the treatment cohort. Clinical data was retrospectively collected on an additional eight patients (P4–P11), highlighting both dominant and recessive inheritance with variable penetrance in PAAND and common gastrointestinal involvement that was not previously appreciated.

Conclusion. In our experience, while anakinra appears safe, it was not superior to biologicals targeting TNF- α in PAAND despite evidence directly implicating dysregulated IL-1 β signalling.

Key words: PAAND, MEFV, pyrin, neutrophilic dermatosis, anakinra

¹Department of Microbiology and Immunology, KU Leuven, ²VIB Center for Brain and Disease Research, ³Department of Pediatrics, University Hospitals Leuven, ⁴Member European Reference Network for Rare Immunodeficiency, Autoinflammatory and Autoimmune Diseases – Project ID No 739543, ⁵Department of Development and Regeneration, Laboratory of Tissue Homeostasis and Disease, KU Leuven, ⁶Department of Rheumatology, University Hospitals Leuven, Leuven, Belgium, ⁷Laboratory of Lymphocyte Signalling and Development, The Babraham Institute, Babraham Research Campus, Cambridge, UK, ⁸Department of Pathology, UZ Leuven, Laboratory of Translational Cell and Tissue Research, Leuven, Belgium, ⁹Specialized Immunology Laboratory of Dr Shahrooei, Ahvaz, ¹⁰Division of Allergy and Clinical Immunology, Department of Pediatrics, Tehran University of Medical Sciences, ¹¹Research Center for Immunodeficiencies, Tehran University of Medical Sciences, ¹²Pediatric Rheumatology Research Group, Rheumatology Research Center, Tehran University of Medical

Sciences, ¹³Department of Pediatrics, Tehran University of Medical Sciences, Tehran, Iran, ¹⁴Leeds Institute of Rheumatic and Musculoskeletal Medicine, University of Leeds, Chapel Allerton Hospital, ¹⁵NIHR Leeds Biomedical Research Centre, Leeds Teaching Hospitals NHS Trust, Leeds, UK and ¹⁶Department of Laboratory Medicine, University Hospitals Leuven, Leuven, Belgium
Submitted 5 October 2020; accepted 23 February 2021

Correspondence to: Carine Wouters, Department of Pediatric Rheumatology, UZ Leuven, Herestraat 49, 3000 Leuven.
E-mail: carine.wouters@uzleuven.be

*Erika Van Nieuwenhove, Ellen De Langhe, Adrian Liston and Carine Wouters contributed equally to this paper.

Rheumatology key messages

- PAAND remains a clinically distinct entity from FMF, with predominant cutaneous manifestations.
- Treatment of PAAND patients with anakinra did not prove superior to treatment with anti-TNF- α agents.

Introduction

The concept of autoinflammatory diseases was proposed in 1999, after the discovery of the genetic cause of TNF receptor-associated periodic syndrome (TRAPS) and the most prevalent autoinflammatory disease, FMF [1]. FMF is now considered to be caused by gain-of-function mutations in the Mediterranean fever gene *MEFV*, with a gene-dosage effect supported by the occurrence of single mutations and the absence of null mutations in FMF patients with a complete clinical phenotype. More recently, specific heterozygous gain-of-function mutations in *MEFV* were shown by our group to be causal for a distinct autoinflammatory disease coined pyrin-associated autoinflammation with neutrophilic dermatosis (PAAND) [2]. These mutations (S242R, E244K) disturb the phosphorylation of S242 and the inhibitory 14-3-3 binding site, thereby inducing spontaneous inflammasome formation. PAAND is characterized by chronic systemic inflammation with fever, elevated acute-phase reactants (APR), arthralgia and myalgia, and neutrophilic dermatosis (e.g. acne, pyoderma gangrenosum). PAAND is recognized as a clinical entity distinct from FMF, which is dominantly inherited through specific heterozygous mutations [2, 3].

Pyrin is a specific downstream immune sensor for bacterial modifications of Rho GTPases resulting in GTPase inactivation, including alterations elicited by glycosyltransferase TcdB [4]. RhoA regulates inhibition of pyrin activity through activation of serine-threonine kinases PKN1 and PKN2, which phosphorylate pyrin at S208 and S242, enabling binding of inhibitory signalling molecule 14-3-3. Loss of 14-3-3 binding to mutant pyrin in PAAND patients was shown to result in increased spontaneous inflammasome formation *in vitro*, with excessive IL-1 β production and caspase-1-dependent pyroptosis [2]. Furthermore, increased levels of cleaved caspase-1 and IL-1 β in skin biopsies from PAAND patients with moderate systemic elevation of cytokine production provided rationale for the initiation of treatment targeting IL-1 β . While the original report demonstrated normalization of APR in one patient upon the introduction of treatment with anakinra [recombinant IL-1 receptor antagonist (IL-1RA)] [1], a recent case of PAAND was refractory to treatment with anakinra, whereas adalimumab (anti-TNF- α , Humira®) elicited an immediate and sustained clinical response [3]. At present, there is no consensus on which therapy should be offered to PAAND patients.

To evaluate the efficacy and safety of IL-1 β targeting treatment in PAAND patients, we undertook an open-label pilot study and gathered available data on

treatment responses in the remaining currently identified PAAND patients.

Methods

Study design and treatment

The open-label pilot study was designed to evaluate the efficacy and safety of anakinra, an IL-1RA, in PAAND patients. Study design included a preliminary phase where treatment was initiated in three PAAND patients, with the intention to expand the number of patients in case of a favourable response. Other treatments were discontinued 3 months prior to the start of the trial except for NSAIDs or low-dose CS (≤ 4 mg per day), which were kept at a stable dose. Anakinra was introduced at a daily dose of 100 mg via s.c. injections. In case of a partial response, an up-titration to a daily dose of 200 mg was allowed after the first month of treatment.

Patient characteristics

Criteria for inclusion required both genetic confirmation of the S242R variant and active disease at the time of inclusion defined by the elevation of CRP or ESR and presence of neutrophilic dermatosis. Exclusion criteria for treatment included elevation of aspartate transaminase/alanine transaminase (exceeding upper limit of normal by 2-fold), infection with hepatitis B/C, HIV or mycobacterium tuberculosis, or cytopenias. Three patients [patients 1–3 (P1–P3)] from a total of 22 affected individuals in the PAAND kindred previously described (I.6, II.7, II.8) [2] both fulfilled the inclusion criteria and gave informed consent for enrolment and treatment with anakinra. All three individuals suffered from a longstanding history of systemic inflammation with fever, polyarthralgias/arthritis, myalgias, gastrointestinal discomfort with diarrhoea (diagnosis of Crohn's disease in 1/3) and predominant cutaneous inflammation comprising of chronic pustular acne, recurrent pyoderma gangrenosum and sterile abscesses with neutrophilic small-vessel vasculitis upon histopathological examination. Written informed consent was obtained from each participant, and the study was approved by the ethical committee of UZ Leuven (S52653). In addition, retrospective clinical and treatment data were collected on two more families, including two affected S242R carriers from the originally reported UK family [2] and two Iranian siblings homozygous for the S242G mutation not previously reported. This study was conducted according to the declaration of Helsinki, and the

study was approved by the Ethics Committee of University Hospitals Leuven.

Assessments

Study visits were scheduled at baseline, week 2 (W2), W4, W8 and W12, and upon extension of treatment W20, W28, W36, W44, W52 and W54. Skin biopsies were taken at baseline and at W12 of treatment. The pre-specified primary outcome was to evaluate the efficacy of anakinra in PAAND patients. A complete inflammatory response was defined as the absence of systemic inflammation with normalization of APR (CRP, ESR) and $\geq 50\%$ improvement in three or more of the secondary outcomes, without worsening in any of these domains. Secondary outcomes included: (i) improvement of cutaneous lesions as judged by the treating physician and by photographs from each time point based on number and extent of the lesions as well as inflammatory activity; (ii) alleviation of gastrointestinal discomfort or diarrhoea; (iii) reduction in the number of painful or swollen joints determined by the 68 tender and swollen joint count performed by the treating rheumatologist (E.D.L.); (iv) quality of life based on the HAQ completed by the patient; and (v) visual analogue scale assigned by the treating physician (E.D.L.). Partial response was defined as a reduction in APR levels, accompanied by a significant improvement in one or more of the secondary outcomes without worsening in any of these domains. Finally, the treatment was judged a failure in case of clinical worsening in any of the domains. APR, complete blood count and liver set were analysed at each visit. A second objective was the evaluation of safety and tolerance in this patient group. The occurrence of infections, both delayed or immediate local site reactions related to anakinra injections, cytopenias and increased liver enzymes, were specifically monitored at each assessment visit.

Cytokine analysis

Plasma samples collected simultaneously from patients and age-matched controls were stored at -80°C . Cytokine levels were quantified by an electrochemiluminescence immunoassay format using Meso Scale Discovery plates according to the manufacturer's instructions. Data were analysed with Discovery Workbench 4.0. Plasma IL-1 β levels were measured using a human IL-1 β ELISA (R&D Systems, Minneapolis US) according to the manufacturer's instructions.

Immunohistochemistry

IF was performed on skin sections fixed in 10% neutral formalin, embedded in paraffin and antigen-retrieved with pH 9.0 Tris. Sections were blocked and stained with rabbit anti-IL-18 (ab191152), rabbit anti-IL-1 (ab2105, Abcam, Cambridge, UK), mouse anti-IL-1 beta/IL-1F2 Propeptide Antibody (MAB6964, R&D Systems, Minneapolis US) and rabbit anti-cleaved caspase-1 (4199, Cell Signalling, Massachusetts, US) before development with donkey anti-rabbit IgG Alexa Fluor 488 (A-

21206, Life Technologies, California, US), goat anti-mouse IgG Alexa Fluor 647 (A32728, Life Technologies, California, US) and DAPI (D1306, Life Technologies, California, US). Sections were mounted and cover-slipped using Fluoromount-G (SouthernBiotech, Birmingham AL, US) before images were acquired with an LSM780 confocal microscope (Zeiss, Oberkochen, Germany).

Results

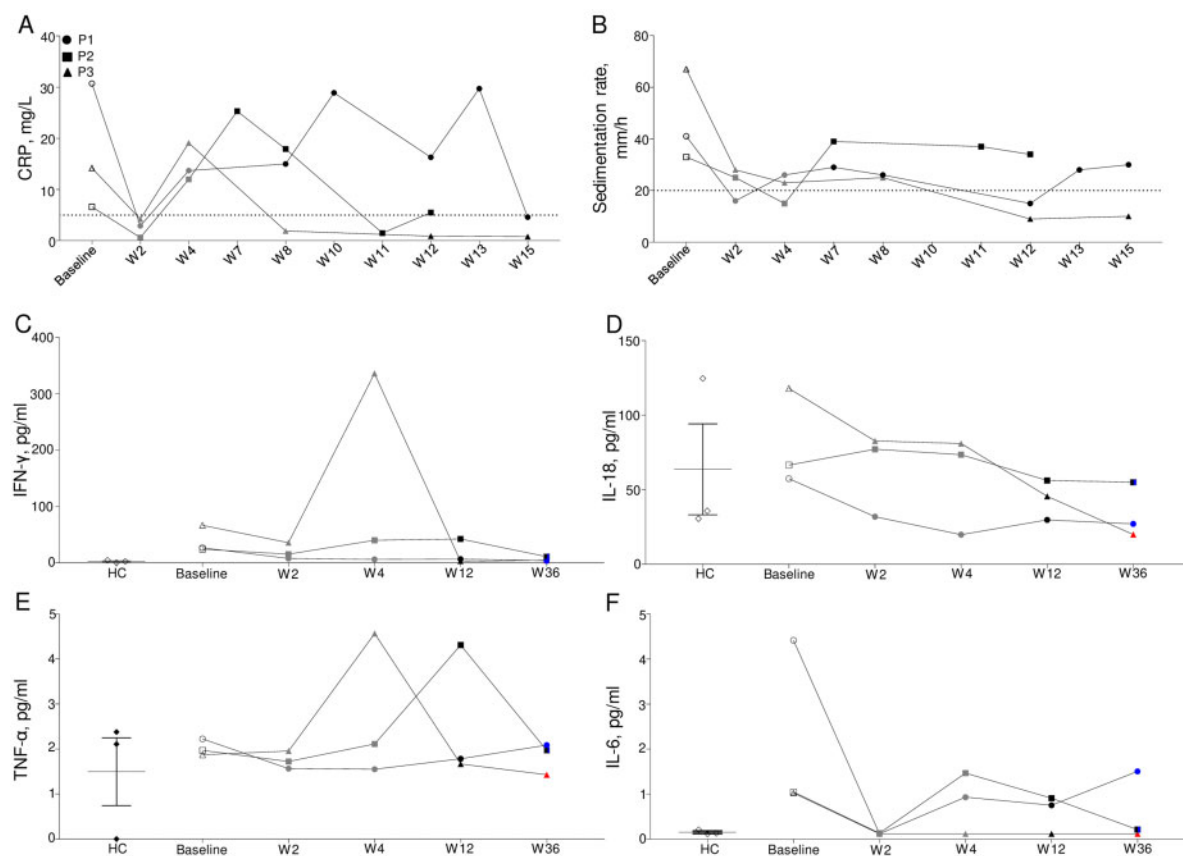
Partial systemic response to anakinra

Three patients from the same kindred published in the original report with active disease were enrolled and treated with anakinra (Table 1). While fever remained absent throughout the clinical follow-up, in all three patients, we documented normalization of CRP values and a reduction in ESR upon initiation of daily s.c. injections of anakinra 100 mg (Fig. 1A and B). Despite rebound of CRP levels in W4, levels again normalized in two out of three patients thereafter (supplementary Figs S1–S4, available at *Rheumatology* online). The greatest fluctuations in CRP and ESR were observed in P1. Dose escalation to 200 mg was not tolerated due to profound fatigue and malaise, which led to the cessation of anakinra in W20. Subsequently, P1 responded well to colchicine (supplementary Figs S1 and S2, available at *Rheumatology* online) and continued to do well with colchicine (2×0.5 mg) and methylprednisolone 4 mg, throughout the 2-year follow-up, with only mild fluctuations in CRP levels. P2 achieved good control of systemic inflammation, apart from two clear inflammatory episodes coinciding with a recurrence of pyoderma gangrenosum in W4 and arthroscopic surgery on his shoulder in W47 (supplementary Fig. S3, available at *Rheumatology* online). The flare in W7 was brought under control by increasing the dose of anakinra to 200 mg and resolved more quickly than previous episodes of pyoderma gangrenosum. In P3, inflammatory parameters remained suppressed except for a rise in W4. However, the patient opted out of treatment with anakinra in favour of adalimumab in W18 due to persistent cutaneous involvement. The brief CRP elevation seen in W4 was presumably in response to a viral infection, supported by a significant increase in IFN- γ levels (Fig. 1C). Increased values of IL-1RA proved adequate compliance of the enrolled patients (data not shown). While not significantly elevated at baseline, IL-18 values showed a declining trend throughout the follow-up period (Fig. 1D). Serum TNF- α values fluctuated very little throughout except for P3 at W4 during a viral infection and for P2 at W12, at which point he was largely recovered from an episode of pyoderma gangrenosum (Fig. 1E). Not surprisingly, IL-6 values showed a similar trend to CRP values, rendering CRP and ESR as the most useful markers to monitor biochemical response (Fig. 1F).

TABLE 1 Clinical and biochemical response parameters at baseline and study assessment visit W2, W8 and W12

	P1				P2				P3			
	W0	W2	W8	W12	W0	W2	W8	W12	W0	W2	W8	W12
Anakinra dosage	0	100 mg	100 mg	200 mg	0	100 mg	200 mg	200 mg	0	100 mg	100 mg	200 mg
Fever	–	–	–	–	–	–	–	–	–	–	–	–
Night sweats	+	–	–	–	–	–	+	+	+	–	–	+
Weight loss	+	–	–	–	+	–	–	–	–	–	–	–
Fatigue	+	–	–	–	+	+	+	–	+	+	+	+
CRP	>20 mg/l	–	>5 mg/l	>5 mg/l	>5 mg/l	–	>5 mg/l	>5 mg/l	>5 mg/l	–	–	–
Sedimentation	>40 mm/h	–	>20 mm/h	–	>20 mm/h	>20 mm/h	>20 mm/h	>20 mm/h	>40 mm/h	>20 mm/h	>20 mm/h	–
Cutaneous	Acne ++	Acne ↓	Acne ↑	Acne =	Acne +	Acne ↓	Acne ↑	Acne =	Acne +	Acne =	Acne ↑	Acne ↑
	Folliculitis –	Folliculitis –	Folliculitis –	Folliculitis –	Folliculitis –	Folliculitis –	Folliculitis –	Folliculitis –	Folliculitis –	Folliculitis –	Folliculitis –	Folliculitis =
	SH –	SH –	SH –	SH –	SH –	SH –	SH –	SH –	SH –	SH –	SH –	SH +
	PG –	PG –	PG –	PG –	PG –	PG –	PG +	PG ↓	PG –	PG –	PG –	PG –
GI	Pain ++	Pain +	Pain –	Pain –	Pain –	Pain –	Pain –	Pain –	Pain +	Pain –	Pain +	Pain +
	Diarrhoea +	Diarrhoea –	Diarrhoea –	Diarrhoea –	Diarrhoea +	Diarrhoea –	Diarrhoea –	Diarrhoea –	Diarrhoea +	Diarrhoea –	Diarrhoea +	Diarrhoea –
Musculoskeletal	Painful: 13	Painful: 1	Painful: 0	Painful: 2	Painful: 2	Painful: 0	Painful: 0	Painful: 0	Painful: 9	Painful: 8	Painful: 10	Painful: 11
	Swollen: 0	Swollen: 0	Swollen: 0	Swollen: 0	Swollen: 0	Swollen: 0	Swollen: 0	Swollen: 0	Swollen: 2	Swollen: 2	Swollen: 2	Swollen: 0
HAQ	10/60	6/60	8/60	15/60	8/60	1/60	1/60	0/60	27/60	24/60	32/60	28/60
VAS	62/100	26/100	45/100	50/100	60/100	50/100	NA	35/100	71/100	60/100	65/100	60/100

W: week; P: patient; NA: not available; PG, pyoderma gangrenosum; SH, suppurative hidradenitis; VAS, visual analogue scale.

Fig. 1 Partial suppression of systemic inflammation in PAAND patients treated with anakinra

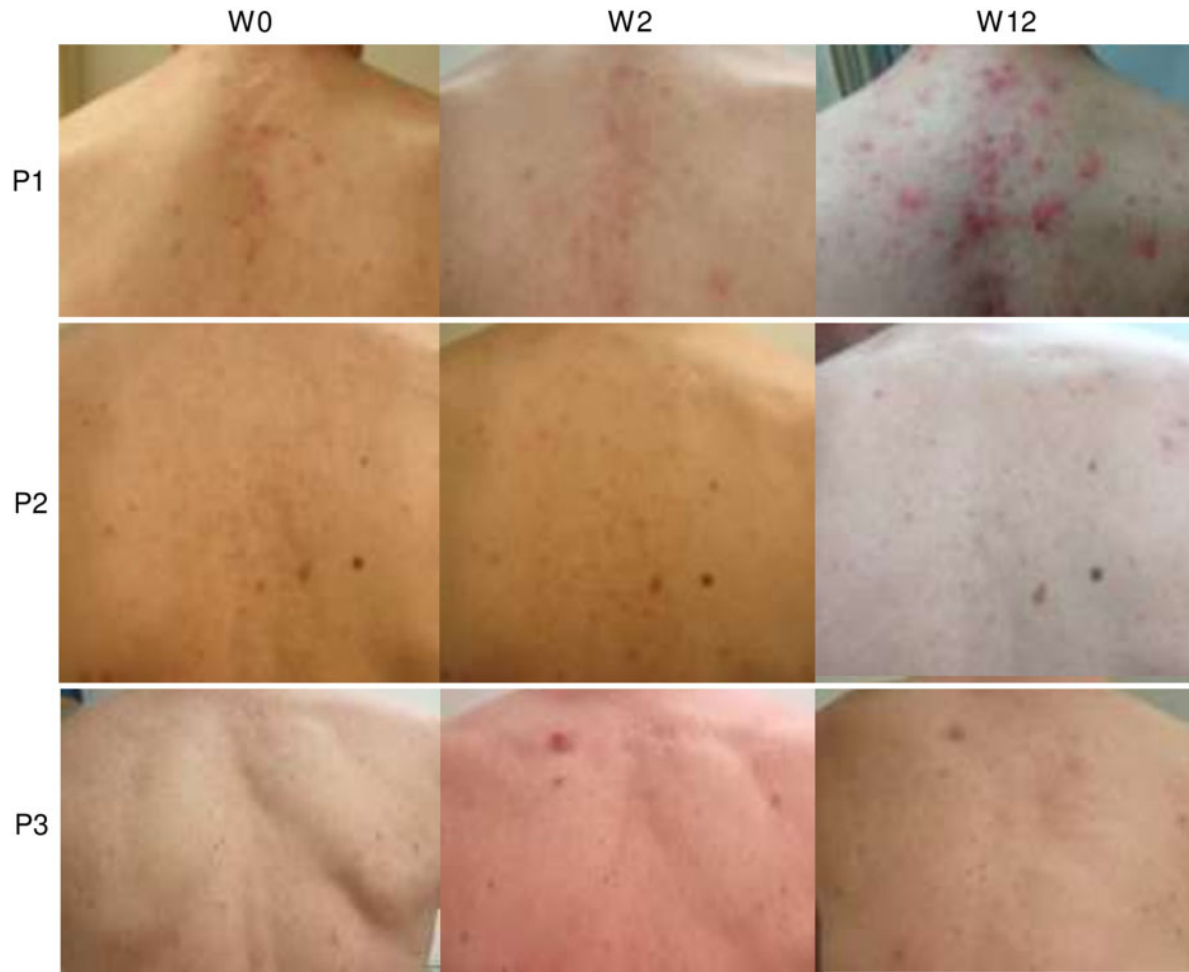(A) Plasma levels of CRP in three included PAAND patients each denoted by a different symbol as indicated in the legend, over time from baseline to week 15 (W15). (B) ESR as in (A). (C–H) Plasma levels of IFN- γ (C), IL-18 (D), TNF- α (E) and IL-6 (F) as in (A). Clear symbols indicate baseline treatment, grey symbols indicate treatment with 100 mg anakinra, black symbols indicate treatment with 200 mg anakinra and blue symbols indicate treatment with colchicine. Mean \pm SEM. PAAND: pyrin-associated autoinflammation with neutrophilic dermatosis; P1–3: patients 1–3.

Limited cutaneous response to anakinra

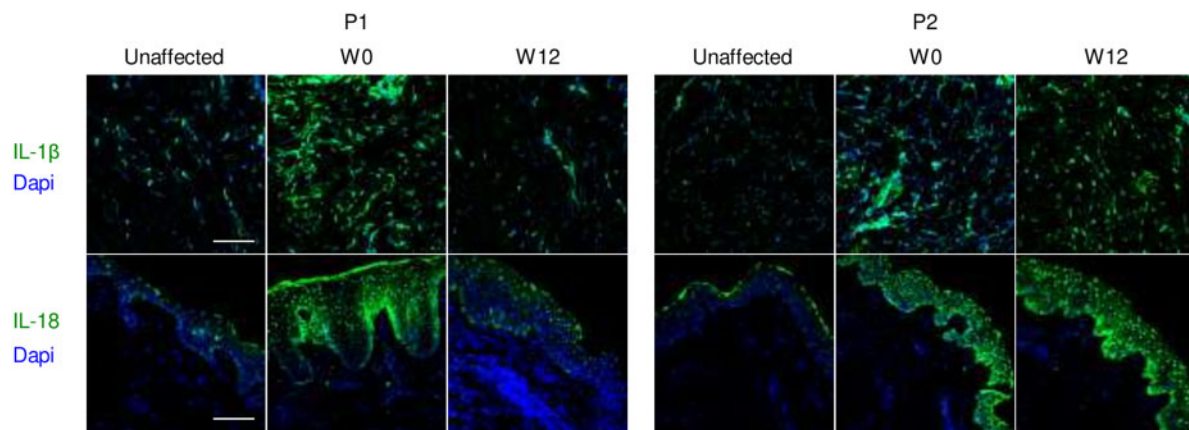
The hallmark cutaneous manifestations of this disorder proved the most refractory to treatment with recombinant IL-1RA. P1 suffered predominantly from severe pustular acne, necessitating regular courses of isotretinoin (Fig. 2, supplementary Fig. S5, available at *Rheumatology* online). While there was a modest improvement of pustular lesions at W2 and W4, by W8 we noted a clear progressive increase in the number of newly arising pustular sores (Fig. 2). A clear flare of the inflammatory lesions ensued, potentially aggravated by increased sun exposure, with biopsy results compatible with increased neutrophilic dermatosis. Interestingly, treatment with colchicine allowed the tapering of CS with only intermittent need for isotretinoin. In P2 we saw an improvement of existing facial acne lesions and onset of fewer pustules under treatment with anakinra (Fig. 2). However, both in W4 and in W44 the patient suffered from a relapse of pyoderma gangrenosum. Doubling of anakinra and administration of i.v. antibiotics in W7 due to positive local cultures for *Staphylococcus aureus* led

to a prompt recovery (supplementary Fig. S5A, available at *Rheumatology* online). Retrospectively, *S. aureus* was not considered pathogenic and improvement was attributed to anakinra. In W22, the addition of colchicine and minocycline suppressed an emerging relapse of pyoderma gangrenosum. Throughout the first year of therapy, P2 also continued to exhibit limited facial acne and recurrent folliculitis. P3 presented at baseline with dorsal acne and at W2 one large pustular lesion or small abscess became apparent on his back (Fig. 2). By W8 facial acne had worsened and a subcentimetric abscess arose in his inguinal area with clear recurrence of suppurative hidradenitis in the axillary and inguinal region by W12 (supplementary Fig. S5B, available at *Rheumatology* online). Upon re-initiation of adalimumab the cutaneous lesions improved (supplementary Fig. S5B, available at *Rheumatology* online).

Skin biopsies at W0 and W12, from both clinically affected and unaffected skin, were stained for IL-1 β , pro-IL-1 β , caspase-1 and IL-18 to evaluate the effect of anakinra on cytokine expression in local tissues (Fig. 3,

Fig. 2 Skin manifestations of PAAND patient treated with anakinra throughout 12 weeks of treatment

Upper back region from patient 1 (P1), P2 and P3 as indicated, at baseline [week 0 (W0)], at W2 and at W12. PAAND: pyrin-associated autoinflammation with neutrophilic dermatosis.

Fig. 3 Persistent pro-inflammatory cytokine expression in skin biopsies of PAAND patients treated with anakinra

Confocal microscopy showing staining of IL-1 β (top panels) and IL-18 (bottom panels) in unaffected skin after treatment and in affected skin both before [week 0 (W0)] and after treatment (W12) with anakinra in patient 1 (P1) and P2. Magnification 20 \times . Scale bar 100 μ m. PAAND: pyrin-associated autoinflammation with neutrophilic dermatosis.

supplementary Figs S6 and S7, available at *Rheumatology* online). While we noted a clear decrease in IL-1 β expression in both affected and unaffected skin, this depletion did not reach the level of unaffected skin for P2 or P3. IL-18 levels markedly decreased in W12 compared with W0 in P1 and P3, whereas IL-18 levels were shown to be unaffected by treatment in P2. Similarly, caspase-1 expression was not sufficiently inhibited by treatment.

Good gastrointestinal response to anakinra

While gastrointestinal symptoms do not predominate the clinical phenotype of PAAND patients, these were present in all three included patients and proved responsive to recombinant IL-1RA. At baseline, P1 suffered from chronic abdominal discomfort and episodic diarrhoea. Persistent alleviation of pain was achieved by W2 of treatment with normalization of stool consistency and recurrence of symptoms in W24 upon withdrawal of anakinra. P1 remained free from gastrointestinal manifestations under colchicine treatment throughout the 2-year follow-up period. P2 was in follow-up for colorectal polyps and sterile perianal abscesses and experienced sporadic diarrhoea and rectal mucus discharge. Following treatment with anakinra we noted swift amelioration of rectal discharge but persistence of occasional loose stools with exacerbation of diarrhoea under colchicine treatment. P3 had a long-standing history of Crohn's disease, treated with TNF antagonists. Persistent abdominal pain and loose stools quickly responded to anakinra and recurred after switching from anakinra to adalimumab in W18.

Mixed musculoskeletal response to anakinra

At baseline P1 manifested mild arthritis of the right wrist, inflammatory limb-girdle pain, painful MTP joints, limited mobility and pain in the left shoulder, and limited internal rotation of both hip joints. By W2 the patient reported an improvement in overall mobility with pain limited to the left shoulder. In W8 there were no painful joints clinically but by W12 the patient experienced a recurrence of girdle pain with morning stiffness and bilateral shoulder pain. P2 presented at baseline with primarily mechanical joint pain in both shoulders. The pain gradually diminished, and by W8 the patient reported no musculoskeletal discomfort. P3 was known with IBD-related HLA B27⁺ SpA. At baseline, he suffered from synovitis, in particular of both hips and shoulders, which subsided throughout treatment. However, the patient continued to suffer from mechanical arthralgias. Whole-body MRI performed in W18 excluded any residual inflammatory changes.

Adverse events

P1 developed classical psoriatic lesions in his lumbar region from the third day of treatment with anakinra, which persisted throughout the follow-up period. He also suffered from local site reactions presenting as an itchy erythematous, raised rash with epidermal abnormalities

(discrete scaling) and peripheral activity with discrete papules at the site of s.c. anakinra injection sites [5]. Lesions were considered possibly related to the administration of anakinra or otherwise eczematous or not specific in nature. The rash resolved spontaneously after the first 2 weeks of treatment. Likewise, P3 suffered from local injection site reactions that persisted into the second month of treatment. Finally, P1 reported general fatigue and vertigo limited to the first 5 days of treatment.

Retrospective data on clinical course and treatment in other PAAND patients

In light of the inconsistent treatment response to anakinra observed in three individuals from the Belgian kindred we sought to collect clinical data on all known PAAND patients to date. We managed to obtain sufficient clinical information on a total of 11 PAAND patients, including 7 from the original Belgian kindred, 2 from the UK family that were included in the primary report and 2 Iranian children with a recessive form of the disease (Table 2). Of note, patients with homozygous S208 mutations in *MEFV* present with recurrent autoinflammatory fevers distinct from PAAND with failure to thrive, oral ulcers, intestinal involvement, leucocytoclastic vasculitis, lymphadenopathy and arthralgias, and were not included in this study [6]. Elevated APR have been observed in all PAAND patients (Fig. 4). However, depending on the severity of a particular patient's disease we have observed both the presence of chronic and/or episodic inflammation in our cohort. Serum amyloid A levels were only determined in the two patients from the UK and were shown to be increased. No PAAND patients have been diagnosed with chronic kidney disease or amyloidosis. Skin manifestations are the hallmark of this disorder and were found in all but one patient. The most common presentation was neutrophilic dermatoses, with three of these patients suffering from suppurative hidradenitis. Acne was unresponsive to anakinra and present in the majority of patients, but for some individuals this was only attributed to their underlying inflammatory disease following their genetic diagnosis. Gastrointestinal manifestations were also found in all but one patient including recurrent oral ulcers, abdominal discomfort, diarrhoea and rectal mucus discharge, including two patients with a formal diagnosis of mononuclear infiltration in *I. propria* Crohn. Polyarthralgias or myalgias and/or arthritis were present in 9 out of 11 patients. While the presence of HLA-B27 was found in 5/7 patients, these individuals all originated from the same multigenerational family. One patient presented with cardiac decompensation at the age of 13 years due to a dilated cardiomyopathy necessitating heart transplantation. The relation to PAAND remains unclear as the cardiac biopsy showed no inflammatory infiltrate. Finally, the two Iranian children both suffered from a failure to thrive.

TABLE 2 Clinical and treatment data on available PAAND patients ($n = 11$), including patients treated with anakinra during this study (P1–P3)

P	Age at onset	AgeSex	Country of origin	Genotype	Systemic inflammation	Skin	Gastrointestinal	Musculoskeletal	Other	Prior treatment	Current treatment
1 (I.6)	29 y	76 yM	Belgium	S242R, AD+		<ul style="list-style-type: none">AcnePsoriasisCutaneous vasculitis at the onset	<ul style="list-style-type: none">DiarrhoeaPainIleal biopsy showed a slightly increased infiltration in the lamina propria, including lymphocytes, plasma cells, and few neutrophils.	<ul style="list-style-type: none">Polyarthralgia/myalgia, recurrent arthritis, HLA-B27⁺Bilateral inflammation of sternoclavicular joints and bilateral enthesopathy of trochanter major on PET-CT		<ul style="list-style-type: none">IsotretinoinMesalazineEnteric budesonideCorticosteroidsFR to anakinra	<ul style="list-style-type: none">Methylprednisolone 3 mg/dayColchicine 1 mg/day
2 (II.7)	10 y	55 yM	Belgium	S242R, AD+		<ul style="list-style-type: none">AcneSuppurative hidradenitisPyoderma gangrenosumErythema nodosum	<ul style="list-style-type: none">DiarrhoeaPain	<ul style="list-style-type: none">Polyarthralgia/myalgia, HLA-B27⁺Bilateral enthesopathy of trochanter major on PET-CT		<ul style="list-style-type: none">Ciclosporin infliximabEtanerceptPR to anakinra	<ul style="list-style-type: none">Anakinra 200 mg/dayMethylprednisolone 1 mg/dayColchicine 1 mg/day
3 (II.8)	43 y	53 yM	Belgium	S242R, AD+		<ul style="list-style-type: none">AcneSterile abscesses	Morbus Crohn (con-IBD-related SpA) firmed on biopsy)	<ul style="list-style-type: none">HLA-B27⁺		<ul style="list-style-type: none">AdalimumabInfliximabMethylprednisolone 4 mgPR to anakinra	<ul style="list-style-type: none">AdalimumabMethylprednisolone 1 mg/dayColchicine 1 mg/day
4 (II.11)	3 y	49 yF	Belgium	S242R, AD+		<ul style="list-style-type: none">Suppurative hidradenitis	<ul style="list-style-type: none">Diarrhoea, pain, erosions in colon with normal biopsy	<ul style="list-style-type: none">Polyarthralgia/myalgia, HLA-B27⁺		<ul style="list-style-type: none">Colchicinestopped due to GI intoleranceHCQMTX	<ul style="list-style-type: none">SSZNSAIDAmitriptyline
5 (II.10)	NA	48 yF	Belgium	S242R, AD+		<ul style="list-style-type: none">Acne	<ul style="list-style-type: none">Recurrent oral ulcers	<ul style="list-style-type: none">Recurrent gonarthritides, HLA-B27⁺		<ul style="list-style-type: none">MTX	<ul style="list-style-type: none">—
6 (III.3)	3 y	26 yM	Belgium	S242R, AD+		<ul style="list-style-type: none">AcneSuppurative hidradenitisSterile abscesses	<ul style="list-style-type: none">—	<ul style="list-style-type: none">PMPerimysial increase in mononuclear infiltrate, HLA-B27 ND	<ul style="list-style-type: none">Dilated cardiomyopathy diagnosed at age 13 y necessitating heart transplantation	<ul style="list-style-type: none">CR to etanercept (0.4 mg/kg twice weekly), stopped due to cardiac decompensationDiuretics and ACE inhibition stopped due to acute renal insufficiency	<ul style="list-style-type: none">TacrolimusMMFPerindoprilSecondary cardiac prevention: soruvastatine, acetylsalicylic acid
7 (III.6)	13 y	20 yF	Belgium	S242R, AD+		<ul style="list-style-type: none">Cutaneous vasculitis (HSP)	<ul style="list-style-type: none">Episodic diarrhoea and pain with positive occult blood and faecal calprotectin 1196 µg/g	<ul style="list-style-type: none">HLA-B27 SpA with oligoarticular involvement		<ul style="list-style-type: none">IVIgI.v. CS (vasculitis)Intraarticular infiltrationSSZCS	<ul style="list-style-type: none">—

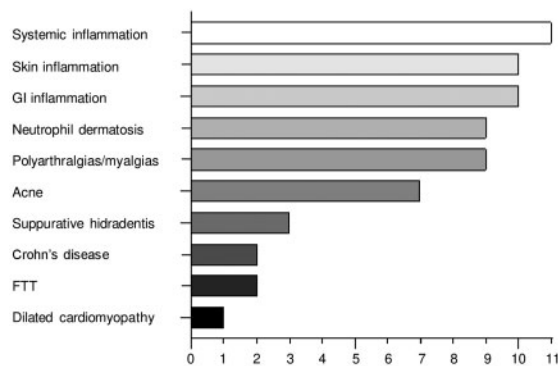
(continued)

TABLE 2 Continued

P	Age at onset	AgeSex	Country of origin	Genotype	Systemic inflammation	Skin	Gastrointestinal	Musculoskeletal	Other	Prior treatment	Current treatment
							<ul style="list-style-type: none">MRI enterography normal. Biopsy showed epithelial hypercrinie and discrete segmental ileitis and pyloric gland metaplasia in the terminal ileum suggestive for Morbus Crohn			<ul style="list-style-type: none">MTXCR to etanercept (0.8 mg/kg weekly)	
8	15y	42yF	UK	S242R, AD+	–		Abdominal pain (Morbus Crohn was excluded)	Polyarthralgia/arthritis, myalgias (calf), HLA-B27 ND, RF+	Proteinuria (nephrotic range)	<ul style="list-style-type: none">FR to MTXPR to monotherapy with prednisolone	Biochemical remission with anakinra and prednisolone but 4 inflammatory episodes over 4.5 y
9	14y	23yM	UK	S242R, AD+		<ul style="list-style-type: none">Purpuric rash at the onsetSevere acne on face and back	Abdominal pain, oral ulcers	Polyarthralgia, enthesitis, and patchy myositis in calves/arms on MRI. Muscle biopsy normal, HLA-B27	Microscopic haematuria, trace proteinuria	<ul style="list-style-type: none">FR to MTXAcne responsive to isotretinoinCR to pulse corticosteroids but relapse after 1 m	Biochemical remission with anakinra but breakthrough myalgias in winter and no effect on acne
10	1 m	5y F	Iran	S242G, AR+		<ul style="list-style-type: none">Pustular lesions on erythematous (cultures negative)Skin biopsy at 1 m shows Sweet syndrome	Episodic gastroenteritis (bacterial cultures negative) at Oral ulcers	Arthritis of wrists at age 1 y, sterile tibia bones at 1.5 y, HLA-B27 ND	<ul style="list-style-type: none">ConsanguinityFTT	<ul style="list-style-type: none">PR to monotherapy prednisolone (5 mg) from age 1 mCR to etanercept SC (0.8 mg/kg/week)	CR with prednisolone 5 mg every other day and colchicine 0.5 mg/day
11	1.5m	3y M	Iran	S242G, AR+		<ul style="list-style-type: none">Mild acneNeutrophilic pustular dermatosisBiopsy at 3 m showed Sweet syndrome	<ul style="list-style-type: none">Perianal abscess at 2 mSurgical correction of intussusception at 5 mRecurrent diarrhoea since infancyBiopsy showed flattened villi and mild mononuclear infiltration in lamina propria	HLA-B27 ND	<ul style="list-style-type: none">ConsanguinityFTTDevelopmental delay, hypotonia, MRI at 12 months showed brain atrophy, hypomyelination and thin corpus callosum	CR to etanercept s.c. (0.8 mg/kg/2 weeks)	CR with prednisolone 5 mg every other day and colchicine 0.25–0.5 mg/day

++ denotes the presence of systemic elevation with CRP ≥ 5 mg/l and/or sedimentation >20 mm/h. AD: autosomal dominant; AR: autosomal recessive; CR: complete response; F: female; FR: failed response; FTT: failure to thrive; M: male; m: months; NA: not available; ND: not determined; P: patient; PR: partial response; y: years.

Fig. 4 Clinical manifestations in PAAND patients with sufficient clinical data ($n = 11$)



Main clinical features of PAAND patients are shown from most prevalent to least prevalent. PAAND: pyrin-associated autoinflammation with neutrophilic dermatosis; FTT: failure to thrive; GI: gastrointestinal.

Discussion

PAAND was first reported in 2016 as an autosomal dominant disease, predominated by neutrophilic dermatosis and long-lasting febrile episodes in the absence of amyloidosis and serositis [2]. Since this first report detailing two families was published, two more independent families with five affected individuals have been identified [3, 7]. While causal mutations remain limited to amino acids S242 and E244, this cohort collectively reveals both dominant and recessive inheritance with variable penetrance. PAAND remains a clinically distinct entity from FMF. While the cutaneous component remains the most striking feature present in 10/11 patients, data from the extended cohort reveals gastrointestinal manifestations are equally present and debilitating. To date, HLA-B27 positivity was only determined and found to be relevant in one kindred with PAAND and thus potentially a confounder contributing to the presence of both IBD-related SpA and HLA-B27⁺ SpA with oligoarticular involvement. The lack of guidelines on PAAND management and the clinical heterogeneity may drive clinicians to HLA-B27 genotyping and subsequent treatment decisions mirroring SpA treatment. In our opinion this also influenced the management of these particular patients. While it is too early to conclude on an association between PAAND and HLA-B27, *MEFV* mutations were shown to predispose to enthesitis-related SpA, and there is an established association between FMF and SpA [8–10]. We propose to consider additional HLA class I testing particularly in patients with important articular and/or intestinal manifestations. Identification of other patients will help elucidate the full scope of PAAND-related features.

Cutaneous manifestations are reminiscent of sterile neutrophil-mediated skin disorders including PASH (pyoderma gangrenosum, acne and suppurative hidradentitis), PAPASH (pyogenic arthritis and PASH), PASS

(pyoderma gangrenosum, acne and SpA) and PAPA (pyogenic arthritis, pyoderma gangrenosum and acne). These entities are known to demonstrate poor response to standard treatment regimens and thus often inflict significant psychological and physical morbidity. While many of these conditions have shown a favourable response to IL-1- and TNF-targeted treatments, the effect is heterogeneous. Whereas joint manifestations were amenable to anakinra, phenotypes predominated by cutaneous symptoms were better managed with anti-TNF [11]. In our own experience with a limited number of PAAND patients, the treatment with anakinra overall did not prove to be superior to treatment with anti-TNF- α agents. We realize that local anakinra concentrations in the neutrophilic lesions may not have been optimized sufficiently. However, the higher dosage was not tolerated by one and was refused by another patient. In contrast, gastrointestinal symptoms were better controlled with anakinra. For future patients, we would opt for treatment with anti-TNF- α in case of predominant and severe cutaneous and/or articular manifestations such as pyoderma gangrenosum or arthritis refractory to first-line treatment. The cutaneous component has responded well to isotretinoin and regression of articular inflammation was achieved in two patients through addition of colchicine. IL-1 blockade can be proposed when the clinical phenotype comprises mainly systemic and/or gastrointestinal inflammation. The heterogeneous response to targeted treatments indicates that we have an incomplete understanding of pathogenesis; the administered biologicals exert an incomplete inhibition of the inflammatory pathways or the organ-specific penetrance of a particular drug is insufficient to achieve complete remission. The latter is supported by our data where we see an incomplete depletion of lesional cytokine levels in the skin.

While neutrophil-mediated skin diseases are largely polygenic in origin, identification of neutrophilic dermatoses in monogenic autoinflammatory conditions has shed light on pathogenesis, including PAPA caused by gain-of-function mutations in the pyrin-activating partner *PSTPIP1* [12]. As clinically overlapping diseases, both polygenic and monogenic forms may result from distinct but congruent genetic backgrounds, including genes related to the inflammasome (*MEFV*, *PSTPIP1*, *NLRP3*, *NLRP12*, *NOD2* and *LPIN2*) and to the γ -secretase complex (*NCSTN*, *PS1*, *PSEN1*) [7, 13]. Cytokines IL-1 β , IL-17 and TNF- α and chemokines including IL-8 and RANTES among others were found to be highly expressed in the lesional skin of pyoderma gangrenosum, promoting the transendothelial migration of neutrophils into the inflammatory site [12]. These alterations are in further support of a common clinicopathological spectrum, where over-activation of the innate immune system, in particular increased inflammasome and IL-1 β signalling, can drive disease with a contributory role of IL-17 [11, 12, 14, 15]. Specifically, in PAAND-related disease, overexpression of IL-1 β was shown to be due to the constitutive activation of the pyrin inflammasome

complex. In our experience, biologicals targeting TNF- α may in fact be more efficacious than anakinra in PAAND in spite of the evidence directly implicating dysregulated IL-1 β signalling [15]. It remains to be determined whether canakinumab may better suppress systemic and local inflammation in these patients. Furthermore, while PAAND pathogenesis differs from FMF and colchicine has no known direct effect on pyrin phosphorylation or 14-3-3 binding, this molecule provided added clinical benefit to PAAND patients [16]. Finally, IL-17 antagonists may be worthwhile to explore further both in PAAND patients and in other systemic forms of pyoderma gangrenosum (15).

Acknowledgements

This work was supported by the VIB Grand Challenges program, the European Union's Horizon 2020 research and innovation programme under grant agreement No. 779295, the KU Leuven (C1), and the Biotechnology and Biological Sciences Research Council (BBSRC) through Institute Strategic Program Grant funding BBS/E/B/000C0427 and BBS/E/B/000C0428. E.V.N. is an Research Foundation Flanders (Fonds voor Wetenschappelijk Onderzoek (FWO)) fellow (SB grant, 1S22716N). Study drug/Kineret (anakinra) was provided by Sobi through a grant agreement (EudractCT—2015-004292-69). The authors wish to acknowledge use of the Babraham Imaging Facility, which is funded through a BBSRC Institute Core Capability Grant. We thank all the patients for their participation in this study.

Disclosure statement: S.S. declares an advisory board participation with Sobi and Novartis, is a speaker at Sobi and Novartis sponsored symposia, and received a grant from Sobi. E.D.L. declares advisory board participation with Novartis, Boehringer Ingelheim and GlaxoSmithKline (GSK). E.D.L. is a medical consultant of Argenx and Amgen. C.W. declares advisory board participation with Sobi and Novartis, and received unrestricted grants to her institution from GSK immune-inflammation, Pfizer, Novartis and Roche. The authors have declared that no other conflict of interest exists.

Data availability statement

The data underlying this article are available in the article and in its online [supplementary material](#).

Supplementary data

[Supplementary data](#) are available at *Rheumatology* online

References

- McDermott MF, Aksentijevich I, Galon J *et al.* Germline mutations in the extracellular domains of the 55 kDa TNF receptor, TNFR1, define a family of dominantly inherited autoinflammatory syndromes. *Cell* 1999;97:133–44.
- Masters SL, Lagou V, Jéru I *et al.* Familial autoinflammation with neutrophilic dermatosis reveals a regulatory mechanism of pyrin activation. *Sci Transl Med* 2016;8:332ra45.
- Moghaddas F, Llamas R, De Nardo D *et al.* A novel pyrin-associated autoinflammation with neutrophilic dermatosis mutation further defines 14-3-3 binding of pyrin and distinction to Familial Mediterranean Fever. *Ann Rheum Dis* 2017;76:2085–94.
- Xu H, Yang J, Gao W *et al.* Innate immune sensing of bacterial modifications of Rho GTPases by the Pyrin inflammasome. *Nature* 2014;513:237–41.
- Kaiser C, Knight A, Nordström D *et al.* Injection-site reactions upon Kineret (anakinra) administration: experiences and explanations. *Rheumatol Int* 2012;32:295–9.
- Hong Y, Standing ASI, Nanthapaisal S *et al.* Autoinflammation due to homozygous S208 MEFV mutation. *Ann Rheum Dis* 2019;78:571–3.
- Gargallo V, Menis D, Delgado Márquez AM, Aróstegui JI, Llamas Martín R. Short-term efficacy of adalimumab in a patient with pyrin-associated autoinflammation with neutrophilic dermatosis. *J Dtsch Dermatol Ges* 2018;16:756–9.
- Akar S, Soysal O, Balci A *et al.* High prevalence of spondyloarthritis and ankylosing spondylitis among familial Mediterranean fever patients and their first-degree relatives: further evidence for the connection. *Arthritis Res Ther* 2013;15:R21.
- Gülhan B, Akkuş A, Özçakar L, Beşbaş N, Ozen S. Are MEFV mutations susceptibility factors in enthesitis-related arthritis patients in the eastern Mediterranean? *Clin Exp Rheumatol* 2014;32(4 Suppl 84):S160–4.
- Kisaarslan AP, Şahin N, Çiçek SÖ *et al.* Evaluation of familial Mediterranean fever patients concomitant with juvenile spondyloarthropathy. *Mod Rheumatol* 2020; doi: 10.1080/14397595.2020.1812809 (online ahead of print).
- Vinkel C, Thomsen SF. Autoinflammatory syndromes associated with hidradenitis suppurativa and/or acne. *Int J Dermatol* 2017;56:811–8.
- Marzano AV, Ortega-loayza AG, Heath M *et al.* Mechanisms of inflammation in neutrophil-mediated skin diseases. *Front Immunol* 2019;10:1059.
- Marzano AV, Damiani G, Ceccherini I *et al.* Autoinflammation in pyoderma gangrenosum and its syndromic form (pyoderma gangrenosum, acne and suppurative hidradenitis. *Br J Dermatol* 2017;176:1588–98.
- Marzano AV, Borghi A, Meroni PL, Cugno M. Pyoderma gangrenosum and its syndromic forms: evidence for a link with autoinflammation. *Br J Dermatol* 2016;175:882–91.
- Cugno M, Borghi A, Marzano AV. PAPA, PASH and PAPASH syndromes: pathophysiology, presentation and treatment. *Am J Clin Dermatol* 2017;18:555–62.
- Gao W, Yang J, Liu W, Wang Y, Shao F. Site-specific phosphorylation and microtubule dynamics control Pyrin inflammasome activation. *Proc Natl Acad Sci USA* 2016; 113:E4857–66.